

## Case Report



## Hydatid cysts of lung and axillary region mimic lung metastasis: A case report

Majid Montazer<sup>1</sup>, Sama Rahnemayan<sup>2,3\*</sup><sup>1</sup>Department of Cardiothoracic Surgery, Imam Reza Hospital, Tabriz University of Medical Sciences, Tabriz, Iran<sup>2</sup>Aging Research Institute, Tabriz University of Medical Sciences, Tabriz, Iran<sup>3</sup>Student Research Committee, Tabriz University of Medical Sciences, Tabriz, Iran

## Article info

## Article History:

Received: 27 Feb. 2020

Accepted: 30 Mar. 2020

e-Published: 12 Apr. 2020

## Keywords:

- Hydatid Disease
- Axillary region
- Lung metastasis

## Abstract

Hydatid cyst disease is one of the zoonoses caused by the larval stage of *Echinococcus granulosus*, mostly involving the liver and the lungs; but its complications can be seen in every site and organ. Sometimes it can cause suspicious and complicated cases that mimic malignancy. For instance, axillary involvement of hydatid cyst is very rare. It is important to differentiate hydatid cyst disease from cancer, since it may show malignant features when pulmonary or other distant organ involvement takes place. In this study, we present a case of multiple masses in the lungs and the axillary region in a 48-year-old woman. The ultrasonography was unable to detect hydatid cysts. Biological values were normal except for serum sodium (Na) and potassium (K); and enzyme-linked immunosorbent assay (ELISA) test was negative. Hydatid cyst was diagnosed while taking a biopsy from the axillary tumor.

## Introduction

Hydatid disease is a zoonotic disease that is mostly caused by the larval stage of *Echinococcus granulosus*. The liver (70% of the cases) and less frequently the lungs (20%) are the main organs that the cysts are located; because at the first place, when digested and absorbed from the intestinal tissue, most of the parasite's embryos are filtered by the hepatic sinusoids; but in 10% of the cases, the embryos reach different and more unusual organs by the way of systemic arterial vessels after passing through the hepatic and pulmonary filters.<sup>1</sup>

In this article, we report a case of a young woman with the presentation of painful palpable axillary mass following multiple masses in both lungs, mimicking lung metastasis; which was diagnosed as a hydatid cyst at right axillary surgical exploration.

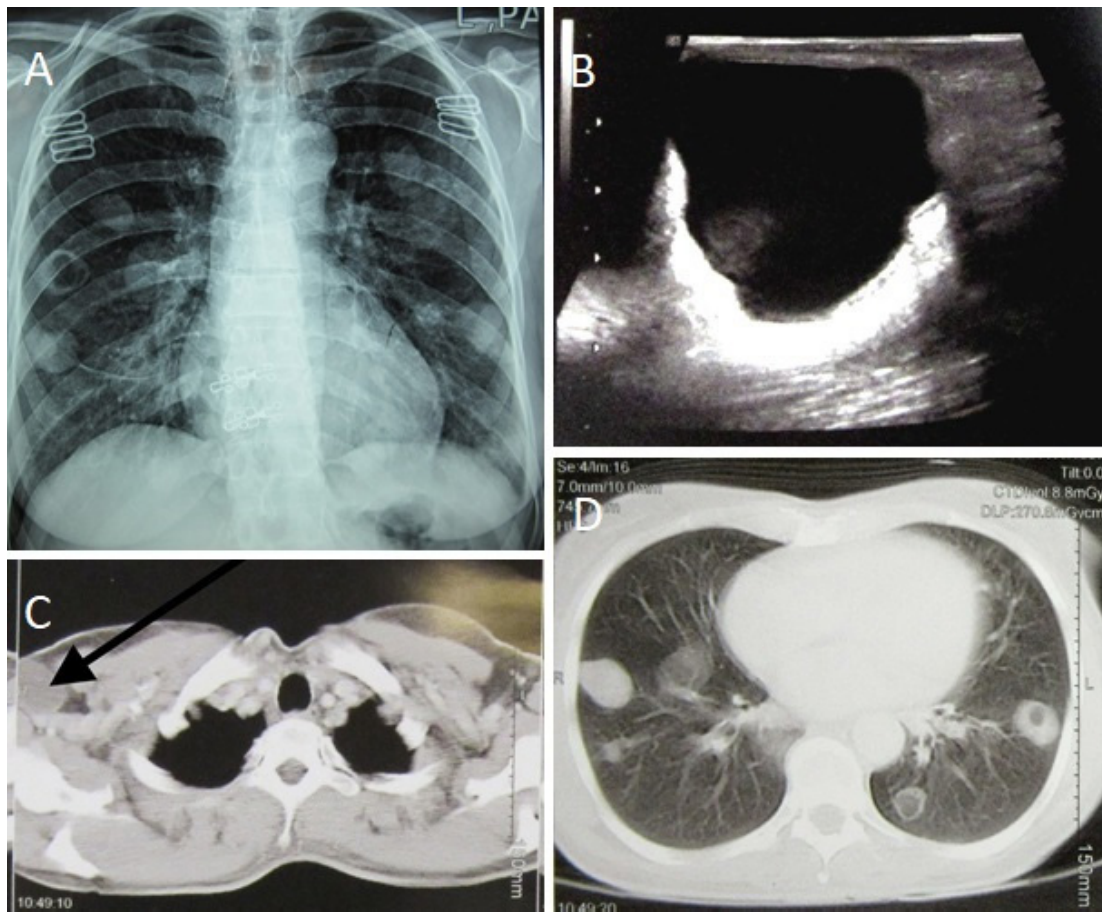
## Case Report

A 48 year-old woman, from a small town, was admitted to our clinic due to presence of round bilateral masses of the lungs in the chest x-ray with a metastatic look, one of which was empty, and also a mass in the right axillary region, which appeared 6 months ago (Figure 1A). The patient mentioned frequent cough, respiratory distress, and recent weight loss (7 kg in 3 months) in her personal

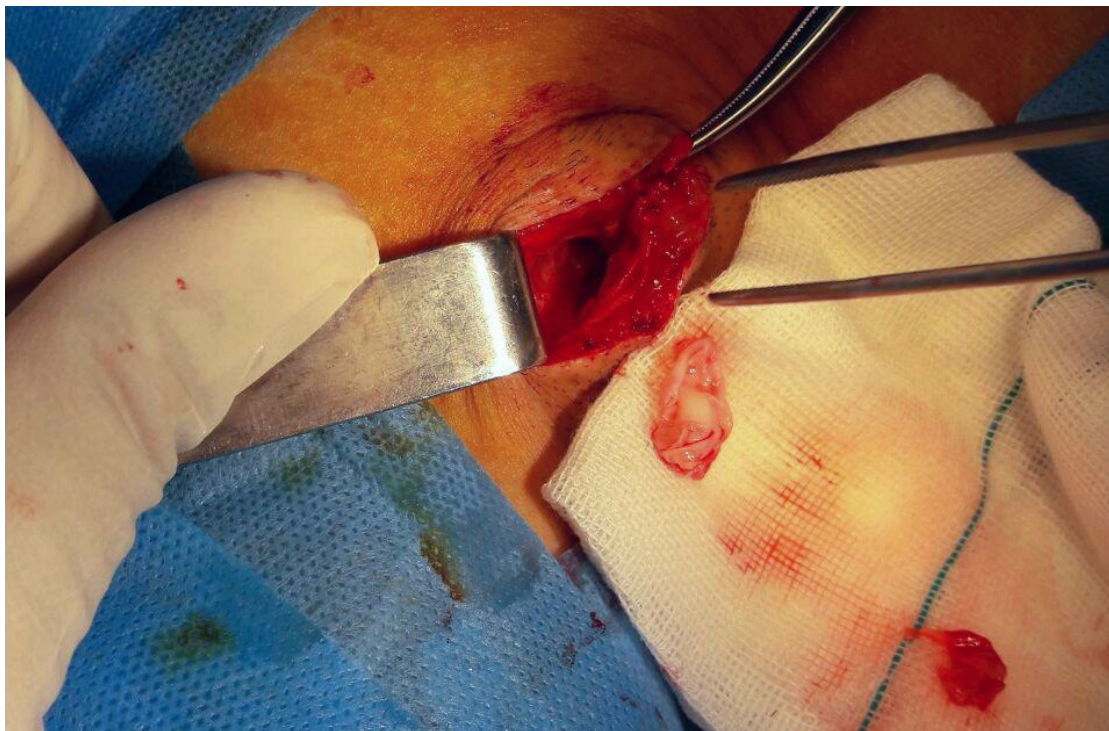
history. At local examination, we found a mobile axillary tumor, of 3 cm in size without tenderness. Hematological values revealed no changes in blood cell count or leukocyte formula. Serum Na level was 145 mEq/L (Na reference range=136-145 mEq/L); and K level was 5.1 mEq/L (K reference range=3.5-5 mEq/L); both of which were slightly elevated. An echinococcal ELISA test was also negative. Ultrasound sonography (USG) examination revealed a sonolucent, homogeneous, well-defined, cystic tumor, and 27×26 mm<sup>2</sup> in size, which was close to the axillary vessels (Figure 1B). A thoraco-abdominal computerized tomography (CT) was performed as a next step, demonstrating a cystic formation of the right axillary region (Figure 1C). The CT-scan also revealed multiple bilateral cystic formations of the lungs, but it without any signs of invasion to the liver, lungs, or spleen ( (Figure 1D). With these findings, the patient was taken to the operation room for the biopsy of the axillary tumor with the pre-operative diagnosis of the probability of lung metastasis to the right axillary region. During the surgery, macroscopic examination of the mass indicated a hydatid cyst that was confirmed with the demonstration of a unilocular cyst that was filled with white gelatinous membrane (Figure 2). The disease was treated by a total excision of the cystic lesion of axillary region and the medical treatment for

\*Corresponding Author: Sama Rahnemayan, Address: Student Research Committee, Faculty of Medicine, Tabriz University of Medical Sciences, Tabriz, Iran. Tel: +989354348479, Email: rahnemayans@tbzmed.ac.ir

© 2020 The Author(s). This is an open access article distributed under the terms of the Creative Commons Attribution License (<http://creativecommons.org/licenses/by/4.0/>), which permits unrestricted use, distribution, and reproduction in any medium, provided the original work is properly cited.



**Figure 1.** Radiologic findings. (A) Chest x-ray of the patient. (B) Ultrasound imaging of the patient. (C) CT image of the patient's axillary region. (D) CT image of patient's lungs.



**Figure 2.** Intraoperative appearance of the cyst.

the hydatid cysts of the lungs. The patient completed the postoperative period without any special concerns and was discharged 2 days after the operation on albendazole 400 mg bid for 6 one-month cycles with 2 weeks off periods in each cycle. During the follow-up and after completion of 6-month treatment course, the symptoms were relieved, and the chest x-ray was clear after 1 year showing no cysts either in the lungs, or the axillary region. Patient's informed consent was obtained.

### Discussion

Differential diagnoses of axillary cystic lesions include a very wide range, but the majority of lesions can be divided into two categories of parasitic and non-parasitic cystic formations. Non parasitic cystic formations include cystic hygromas, inclusion cysts, and ganglionic cysts. For this reason, hydatid cyst and malignancies should be considered as differential diagnosis for an axillary soft tissue mass.<sup>2</sup>

Hydatid cyst is mostly diagnosed by radiology. Ultrasonography can also be used for the screening of the axillary cysts due to its high sensitivity and low cost, but histopathological examination is mostly the accurate and definitive way of hydatid disease diagnosis.<sup>3</sup> In our patient, it was not possible to differentiate hydatid cyst by USG and CT; but we had to suspect it. For this reason, it would be better to perform a biopsy in line with this suspicion.

Current therapeutic methods for hydatid cyst management are including surgery, percutaneous drainage, and medical therapy. The curative treatment of all soft tissue hydatid cysts is by total excision of the cyst with maximum care, in order to prevent their rupture.<sup>4</sup>

Hydatid cyst disease is one of prevalent health issues in developing countries; and its complication can be seen in almost every organ; therefore, it can sometimes cause suspicious and complicated cases that mimic malignancy. For this reason, when discovering tumors of the lungs or the axillary region, it should call to mind hydatid cyst as one of the differential diagnosis of the disease. In this case, axillary explore excluded other differential diagnosis and importantly manifested permanent diagnosis.

### Conflict of Interest

None declared.

### Authors' contribution

MM: Investigation, project administration, supervision, validation, visualization. SR: Investigation, writing – original draft, writing – review & editing.

### Informed Consent

Written informed consent was obtained from the patient for publication of this case report and accompanying images.

### Funding

The authors declared that this study has received no financial support.

### References

1. Hakverdi S, Sayar H, Yaldiz M, Erdoğan S, Akansu B, Canda MS. [Unusual localization of echinococcosis in Cukurova (134 cases)]. *Turkiye Parazitol Derg.* 2009;33(1):77-81.
2. Saylam B, Vural V, Duzgun AP, Ozer MV, Coskun F. Primary hydatid cyst of the axilla: report of a case. *Med Princ Pract.* 2012;21(1):79-81. doi: 10.1159/000331900.
3. Zangeneh M, Amerion M, Siadat SD, Alijani M. Primary hydatid cyst of the axillary region: a case report. *Case Rep Med.* 2012;2012:362610. doi: 10.1155/2012/362610.
4. Damak T, Triki A, Chargui R, Laamouri B, Chemlali M, Bouzaïene H, et al. Hydatid cyst mimicking an axillary lymph node. *Tunis Med.* 2012;90(11):836-7.